

Case report

Massive intrathoracic extrapleural haemangiopericytoma: deployment of radiotherapy to reduce vascularity

Anjum Jalal, K. Jeyasingham*

Department of Thoracic Surgery, Frenchay Hospital, Frenchay, Bristol BS16 1LE, UK

Received 8 February 1999; received in revised form 7 June 1999; accepted 15 June 1999

Abstract

Haemangiopericytoma is a rare, highly vascular, slow-growing tumour which has both malignant and benign varieties. We report a case of a 63-year-old man in whom it was treated by initial radiotherapy followed by complete surgical excision. The preoperative radiotherapy markedly reduced the vascularity of the tumour. A brief review of the pathology and nature of tumour is provided. © 1999 Elsevier Science B.V. All rights reserved.

Keywords: Haemangiopericytoma; Chest wall tumor; Radiotherapy

1. Introduction

Haemangiopericytoma of the chest wall is a rare condition. Only a few isolated case reports are available in the literature. The intrapulmonary variety of the same tumour is relatively more common. The tumour usually presents late as it grows very slowly, producing a few vague symptoms. The large size of such tumours with high vascularity makes surgical excision relatively difficult. We used preoperative radiotherapy which significantly reduced vascularity of the tumour and made complete resection much easier.

2. Case report

A 63 year old man presented with a sharp pleuritic pain which he experienced while coming out of his car. This was accompanied by a slowly progressive shortness of breath and a general feeling of being unwell. At the time of admission he was in a very stable clinical condition. There were no abnormal clinical signs except a dull percussion note over lower part of the back of left chest. Detailed full blood count as well as biochemical tests showed results within normal range. His chest X-ray showed a diffuse opacity in left lower zone with ground glass appearance. Since this patient had a hiatus hernia repaired transabdom-

inally several years ago, we initially considered a recurrence with herniation of omentum in the chest. However, in the absence of significant abdominal signs, there was a strong suspicion that the shadow could be due to an intrathoracic neoplasm.

The patient was observed for 24 h during which time an upper GI barium study was conducted which ruled out herniation of gut. A contrast CT scan was performed which showed a mass-lesion of variable texture and areas of contrast enhancement (Fig. 1). We performed a limited thoracotomy with two differential diagnoses in mind including, either a very vascular tumour or a herniated omentum. On entering the chest a 10 × 10 cm extrapleural tumour was encountered arising from the posterior chest wall. There was profuse bleeding and therefore a small piece of tissue was taken for biopsy and further resection was abandoned.

The histology demonstrated characteristic features of adult haemangiopericytoma which are described in Section 3. The mitotic activity was low, suggesting a benign tumour.

The patient was then treated with radiotherapy. The total dose of radiation was 55 Gy divided in 20 fractions given over a period of 1 month. He was readmitted 12 weeks later for resection. A repeat CT scan with contrast was performed which showed diminished uptake in the periphery of the tumour (Fig. 2). Surgical resection was embarked upon and thoracotomy revealed more favourable conditions. There were multiple adhesions between the lung and tumour which were divided without any difficulty. The tumour itself was covered with pleura. An extrapleural plane between the chest cage and the tumour was defined and the tumour was

* Corresponding author. Tel.: +44-1454-773691; fax: +44-171-970-1960.

E-mail addresses: anjumjalal@aol.com (A. Jalal), jeyasingham@btinternet.com (K. Jeyasingham)

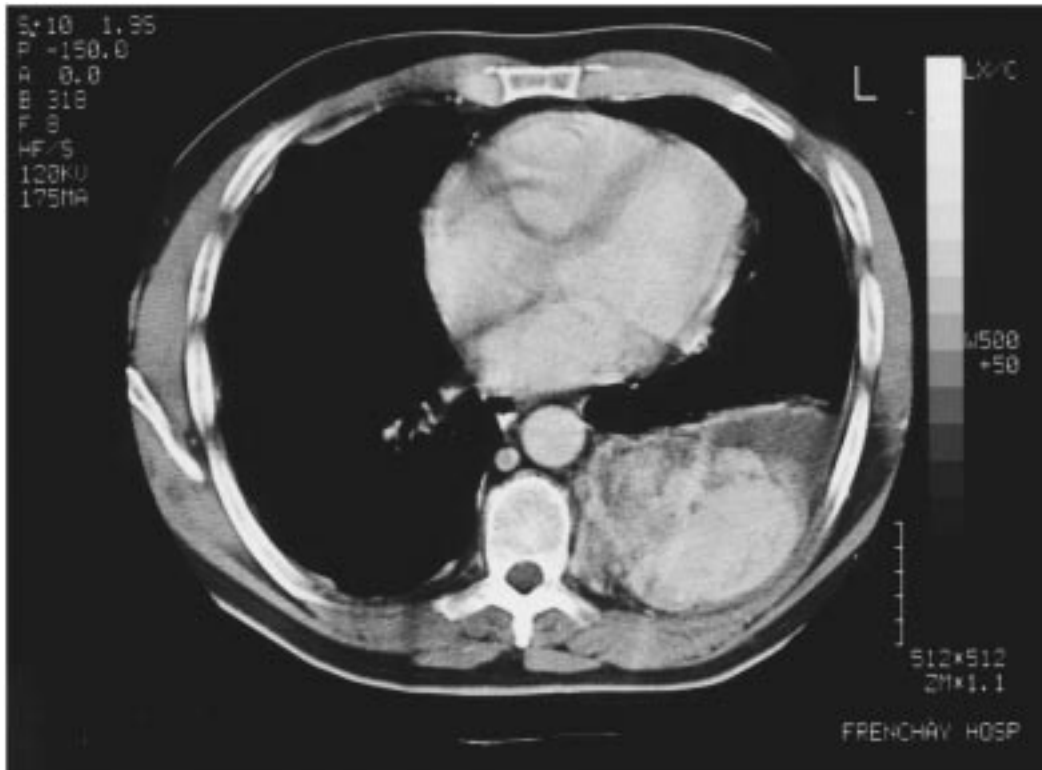


Fig. 1. Pre-radiotherapy contrast CT scan showing highly vascular chest wall haemangiopericytoma.

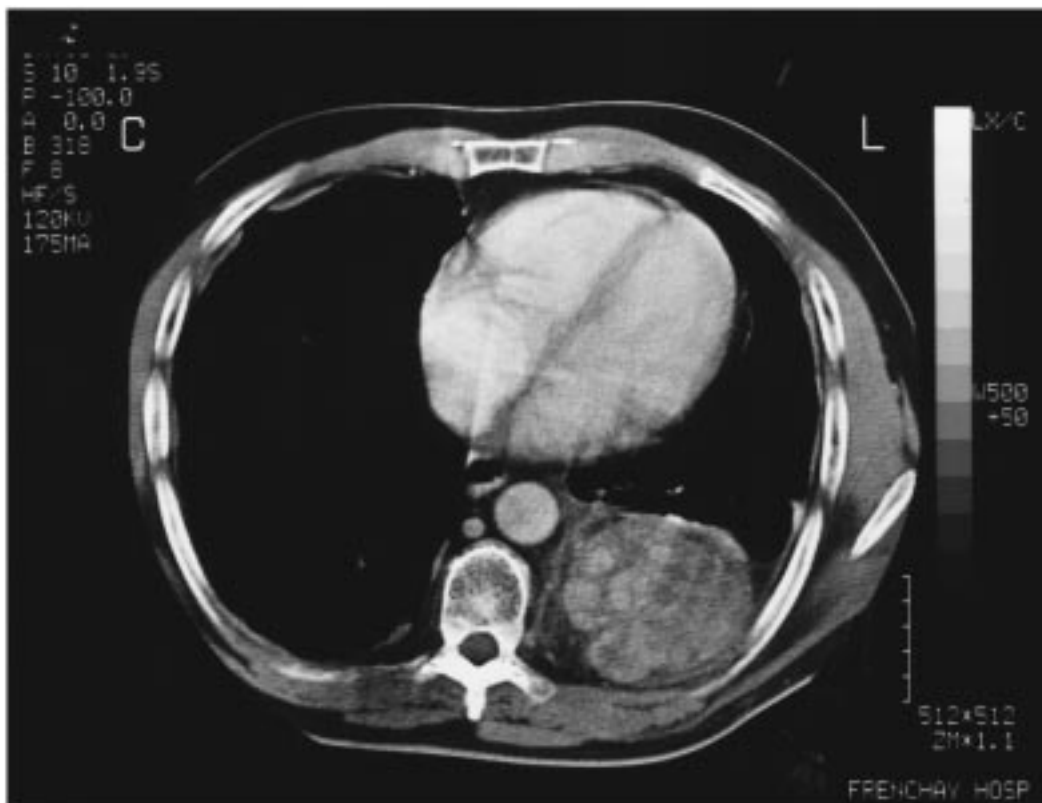


Fig. 2. Post-radiotherapy CT scan showing marked decrease in the contrast uptake by the haemangiopericytoma.

removed in toto. A moderate amount of bleeding was encountered from large feeding vessels arising directly from the aorta. The post-operative recovery was rapid and uneventful. The histological examination confirmed the completeness of resection. No further treatment in terms of chemo- or radiotherapy was given. On follow-up at 6 months the patient had an excellent clinical condition with satisfactory chest X-ray and no signs of recurrence.

3. Discussion

Enzinger and Smith [1] published a series of 106 cases of haemangiopericytomas of different anatomic locations. Their data provided valuable information regarding its nature, presentation and incidence.

Haemangiopericytoma is a tumour derived from pericapsular modified smooth muscle cells. It generally presents in middle and late adulthood. Principal sites of the tumour include lower limb and the retroperitoneal space. Symptoms depend on the location of the tumour and are mostly due to pressure effects on the surrounding structures. Systemic effects are minimal. However, it may occasionally present with hypoglycaemia. This tumour induced hypoglycaemia has been ascribed to the presence of circulating growth factor which has insulin-like activity. This insulin-like growth factor (IGF-II) suppresses endogenous glucose production and enhances glucose utilisation. Although a continuous infusion of somatostatin reduces the circulation levels of IGF-II, it does not effectively control hypoglycaemia and therefore intravenous infusion of glucose is also required. A complete resection of the tumour reverses these abnormal effects completely [2,3].

Adult cases usually follow a benign course but 20–30% of cases do behave in malignant fashion. In infantile cases the tumours are usually subcutaneous and rarely metastasise. However, recurrence twice after excision of sternal haemangiopericytoma in a 5-year-old child has been reported [4]. In an interesting histological study of 11 tumours of infantile haemangiopericytomas, Mentzel and colleagues noticed a marked similarity between infantile haemangiopericytoma and infantile myofibromatosis. They have suggested that there is a broad spectrum of benign myofibroblastic lesions and that infantile haemangiopericytoma represents a different stage of maturation in this spectrum. They have elaborated the similarities between infantile haemangiopericytoma and infantile myofibromatosis and differences between adult and infantile haemangiopericytoma [5].

The histology of adult haemangiopericytoma usually shows a well demarcated but multinodular mass. It is composed of an extensive capillary network with interspersed small basophilic cells. The capillaries are dilated, tortuous and bleed easily. The endothelial lining is usually normal and special stains for reticulin suggest an extravascular origin of the tumour from Zimmermann's pericytes. These pericytes form a part of the external layer around the

endothelium of capillaries. The growth of the tumour is slow and expansive with a gradual compression of surrounding tissues which results in the formation of fibrous pseudocapsule. The tumour therefore does not invade the surrounding tissue and usually presents very late after it has reached a size large enough to produce pressure effects. On microscopic examination the cells are spindle-shaped with cytoplasmic extensions and indistinct borders. The nucleus is round or oval and eccentrically located and contrary to the other mesenchymal tumours, haemangiopericytomas tend to exfoliate in large number on fine needle aspiration. Since other mesenchymal tumours can mimic haemangiopericytomas on fine-needle aspiration, immunohistochemical studies are therefore indicated [6]. The tumour itself resembles synovial sarcoma and mesenchymal chondrosarcoma, therefore extensive sampling of all soft tissue tumours is strongly recommended. There is usually great difficulty in differentiating between benign and malignant varieties. The best diagnostic criterion for malignancy is the presence of more than 4 mitotic figures per 10 high-power fields [7].

Contrast CT scan, MRI and angiography can all be employed for establishment of a provisional diagnosis. CT scan shows a soft tissue mass of smooth margins, hypervascularity and ground-glass appearance. The subpleural location and relatively well-preserved bronchovascular pattern in the lung distinguish it from the intrapleural variety. MRI shows intermediate signals on T₁-weighted images and increased signal on T₂-weighted images [8].

The treatment of choice is radical excision of the tumour in the benign variety and possibly including chest wall in malignant cases. Adjuvant high dose radiotherapy and chemotherapy with doxorubicin hydrochloride has been suggested as the malignant variety has a high risk of local recurrence and distant metastasis [9,10]. However, there is no convincing evidence that radiotherapy alone given before or after the surgical excision would improve the outcome. Nevertheless, on a theoretical basis pre-operative radiotherapy may reduce the vascularity of the tumour and enhance the prospect of achieving satisfactory local excision, which is usually difficult as well as hazardous in very large tumours. We used radiotherapy in the case reported above on the basis of the same hypothesis and observed a marked improvement in vascularity. It helped a great deal in performing a complete surgical resection. We therefore recommend the use of pre-operative radiotherapy in very large haemangiopericytomata of the chest wall.

References

- [1] Enzinger FM, Smith BH. Haemangiopericytoma. An analysis of 106 cases. *Hum Pathol* 1976;7:61–82.
- [2] Benn JJ, Firth RG, Sonksen PH. Metabolic effects of an insulin-like factor causing hypoglycaemia in a patient with a haemangiopericytoma. *Clin. Endocrinol* 1990;32(6):769–780.
- [3] Chung J, Henry RR. Mechanisms of tumour-induced hypoglycaemia

- with intra-abdominal haemangiopericytoma. *J Clin Endocrinol Metab* 1996;81(3):919–925.
- [4] Raafat F, Cameron AH, Mann JR, Stevens MC, Spooner D. Recurrent hemangiopericytoma of the chest wall: report of a case in a 5-year-old boy. *Pediatr Pathol* 1994;14(1):19–25.
- [5] Mentzel T, Calonje E, Nascimento AG, Fletcher CD. Infantile haemangiopericytoma versus infantile myofibromatosis. Study of a series suggesting a continuous spectrum of infantile myofibroblastic lesions. *Am J Pathol* 1994;18(9):922–930.
- [6] Husain AS, Haapaniemi J. Aspiration biopsy cytology of malignant haemangiopericytoma metastatic to the lung. Cytomorphic and immunocytochemical study of a case. *Acta Cytol* 1997;41:1265–1268.
- [7] Fletsher CDM, McKee PH. The circulatory system: vascular tumours. In: McGee JO'D, Isaacson PG, Wright NA, editors. *Oxford text book of pathology*, 2a. Oxford: Oxford University Press, 1992. pp. 938–939.
- [8] Kusumoto S, Nakamura R, Mizoguchi N, Ono S, Watanabe K. Primary intrathoracic extrapulmonary hemangiopericytoma. CT and MR findings. *Clin Imaging* 1997;21(1):51–53.
- [9] Zornig C, Langwieler TE, Weh HJ, Schroder S. Malignant haemangiopericytoma of the chest wall. *Eur J Surg Oncol* 1993;19(1):87–91.
- [10] Sellke FW, Laszewski MJ, Robinson RA, Davis R, Rossi NP. Haemangiopericytoma of the sternum. *Arch Pathol Lab Med* 1991;15(3):242–244.